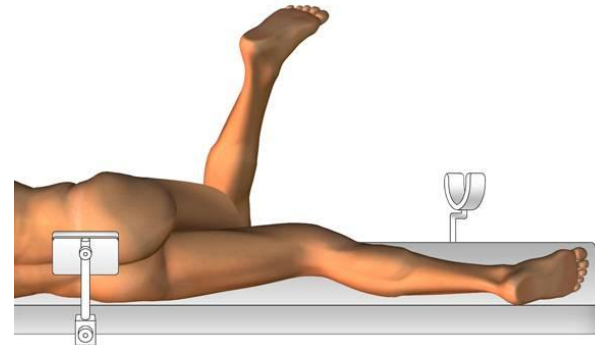
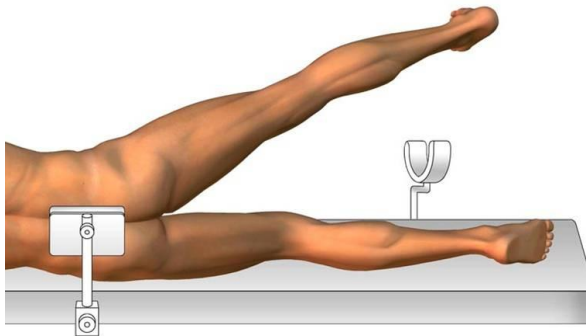
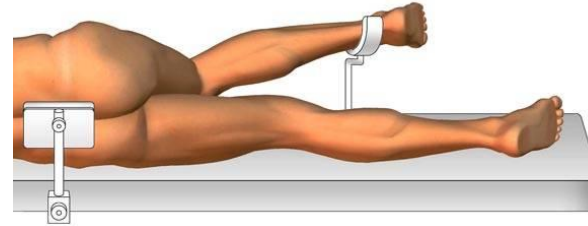
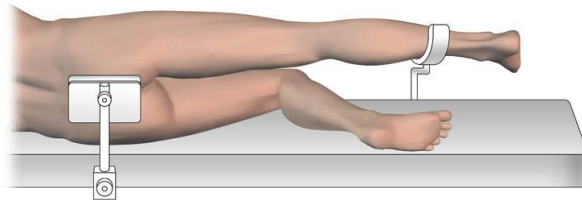


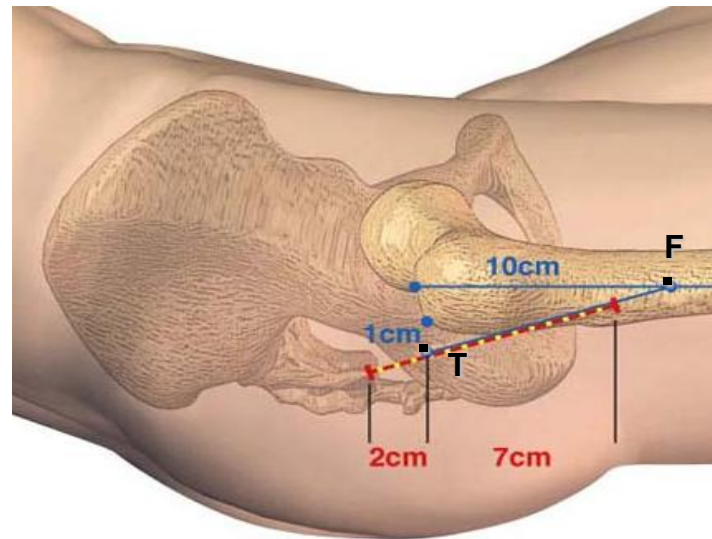
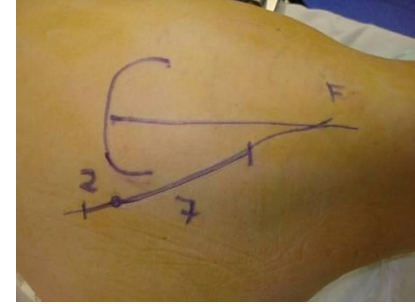
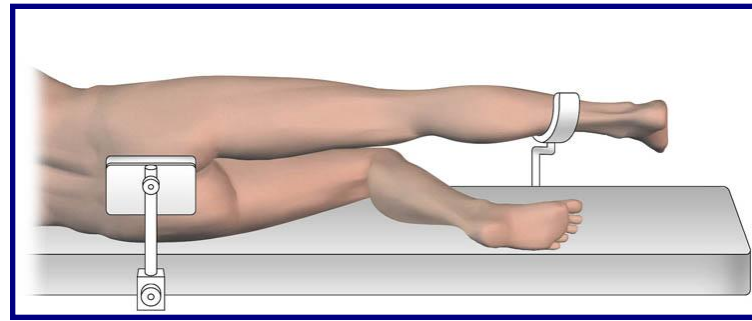
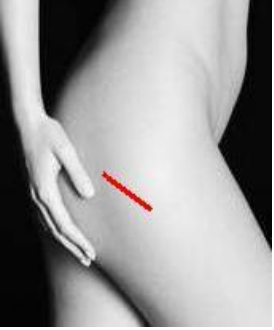Chirurgie mini invasive postérieure

Installation . Exposition

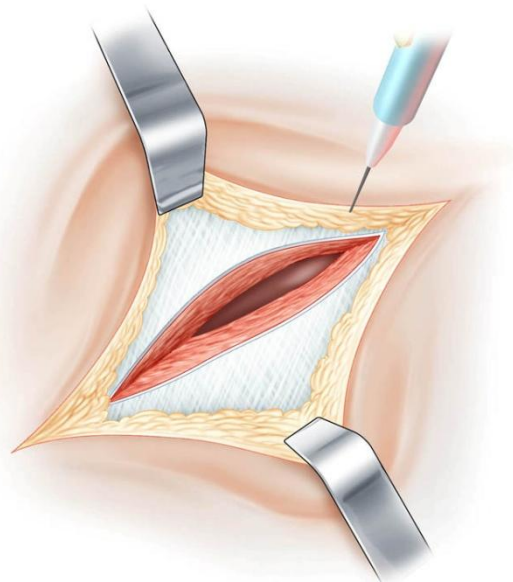
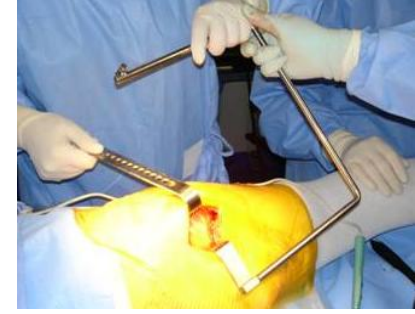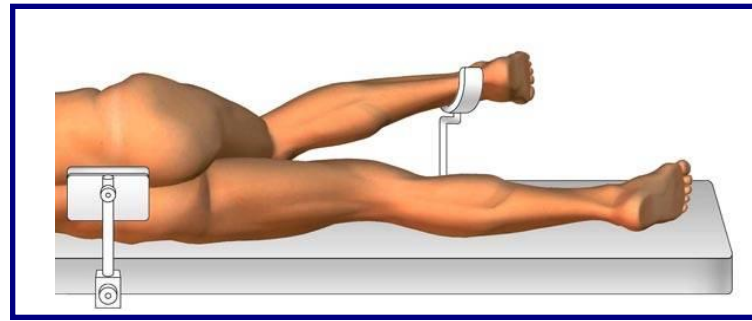
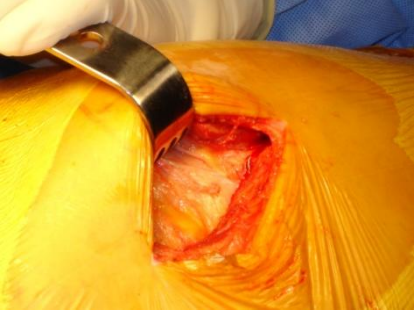
François Prigent



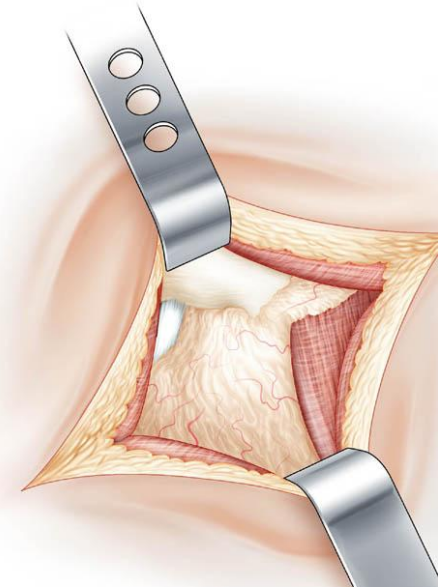
**Quatre positions per opératoire sont utiles
pour tendre et détendre tour à tour les parties molles respectées**



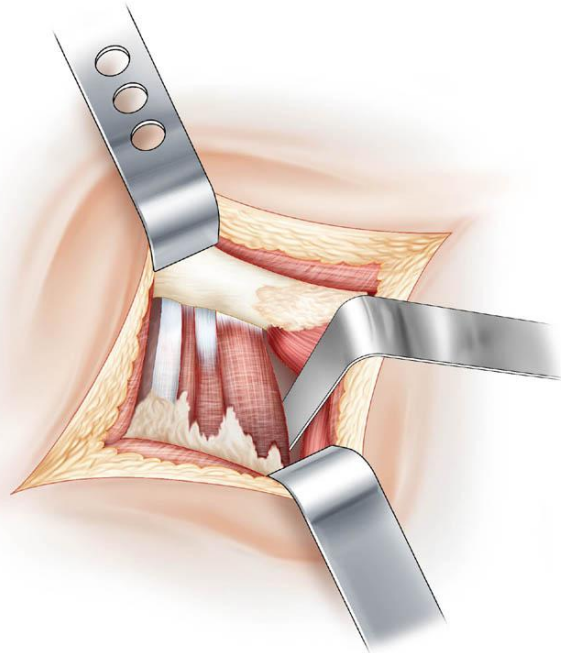
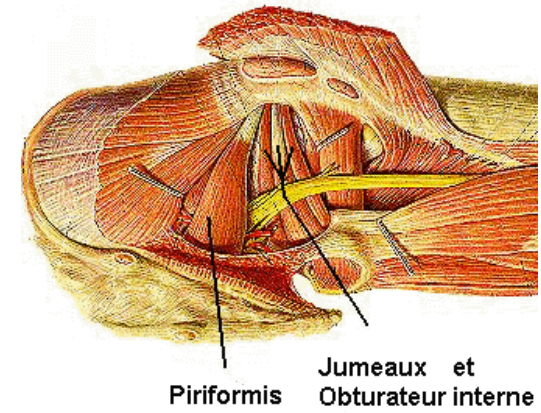
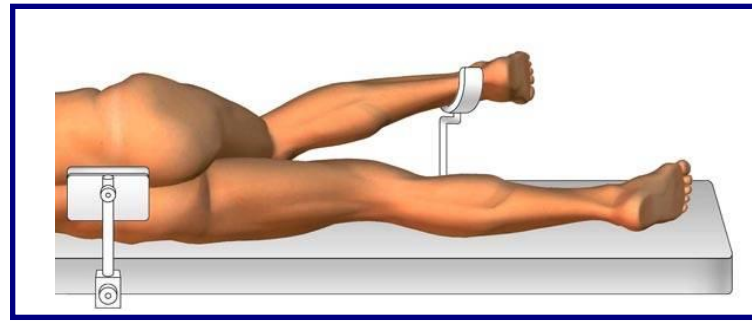
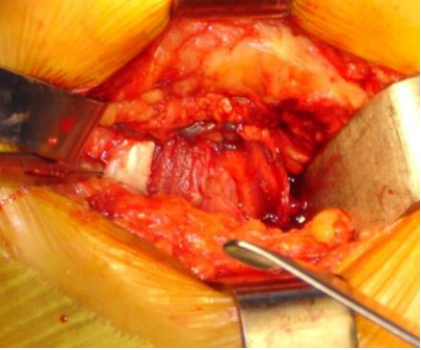
Incision de 9 cm. tracé sur la ligne F T
Point T à 1 cm. en arrière du grand trochanter
Point F à 10 cm. sur l'axe du fémur



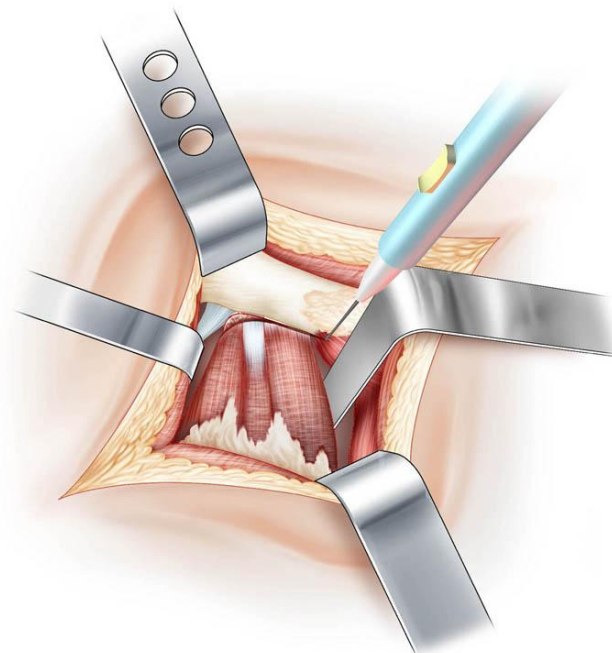
**Incision du plan cutané gras
Exposition du muscle grand fessier**



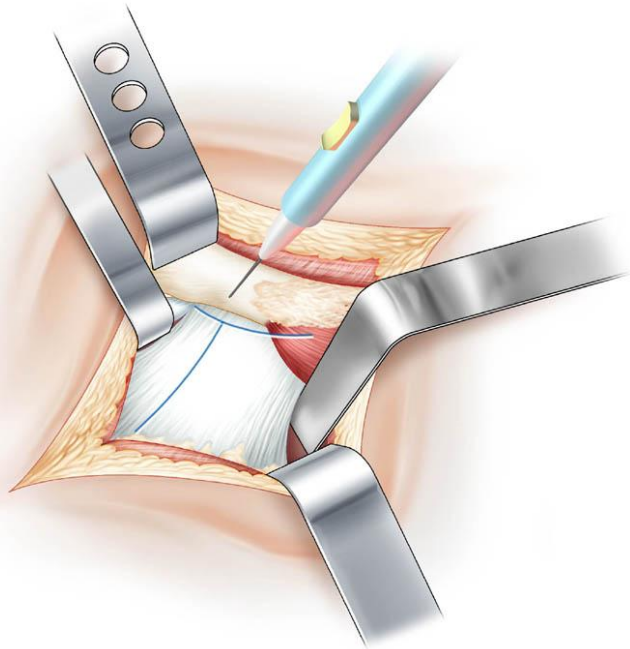
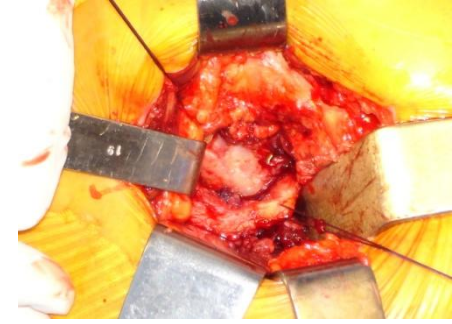
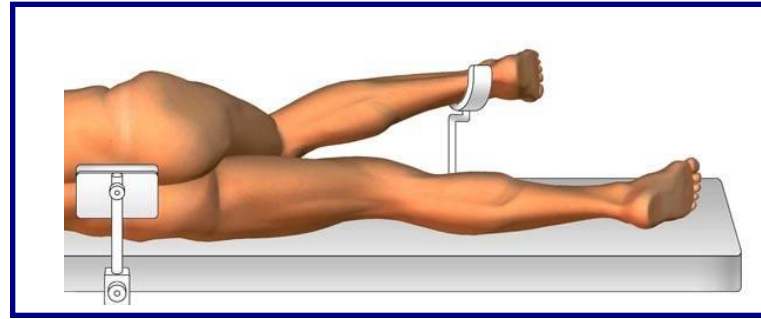
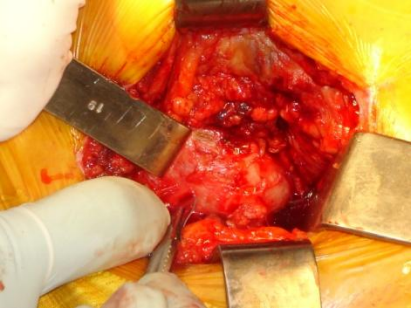
**Discision du muscle grand fessier
Mise en place du cadre de Charnley**



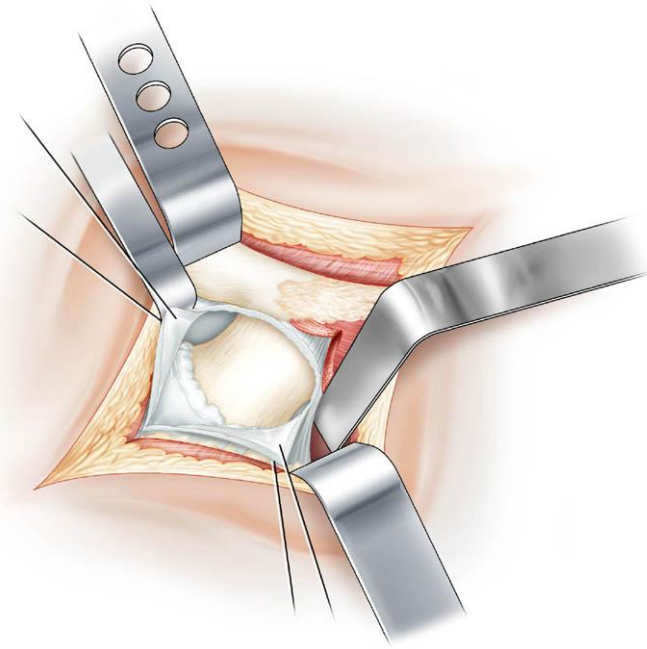
**Le muscle carré crural est récliné
Le tendon du piriformis est individualisé**



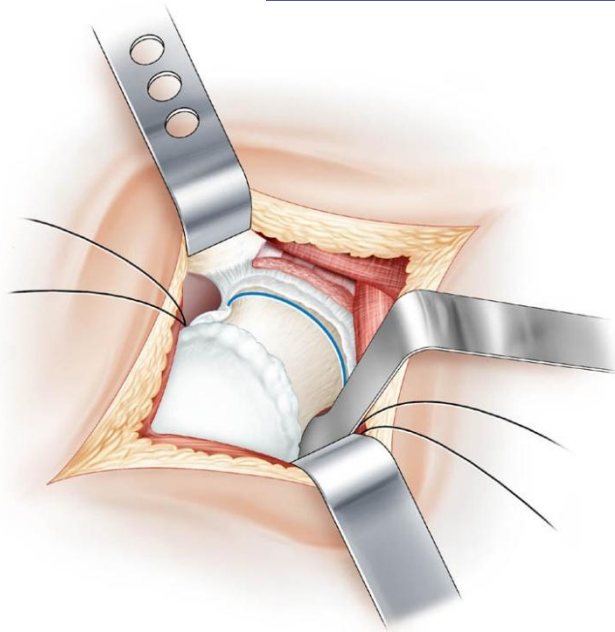
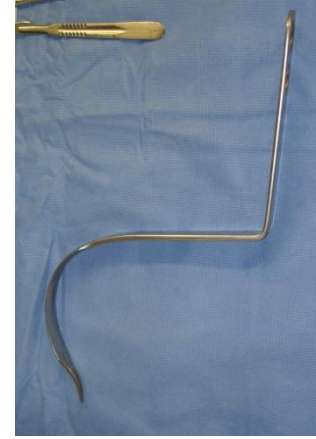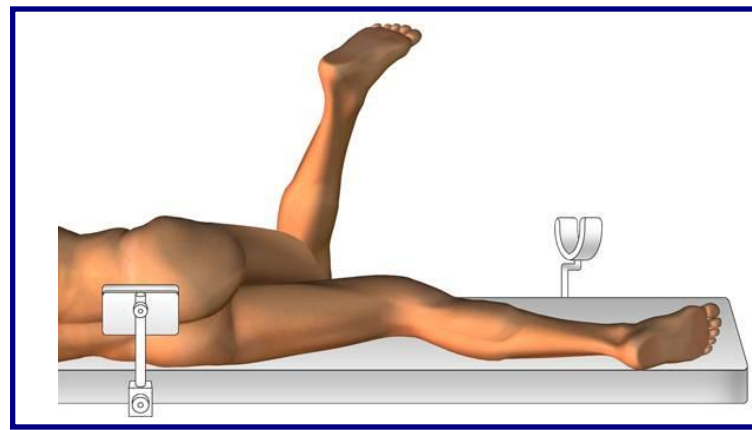
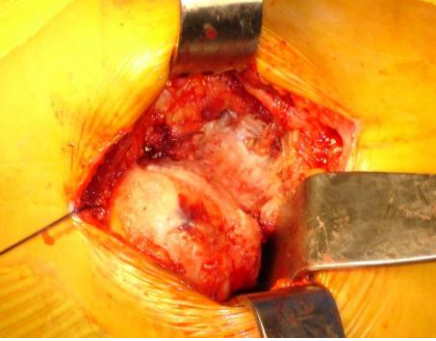**Le tendon du piriformis est écarté
Section des muscles jumeaux
et de l'obturbateur Interne**



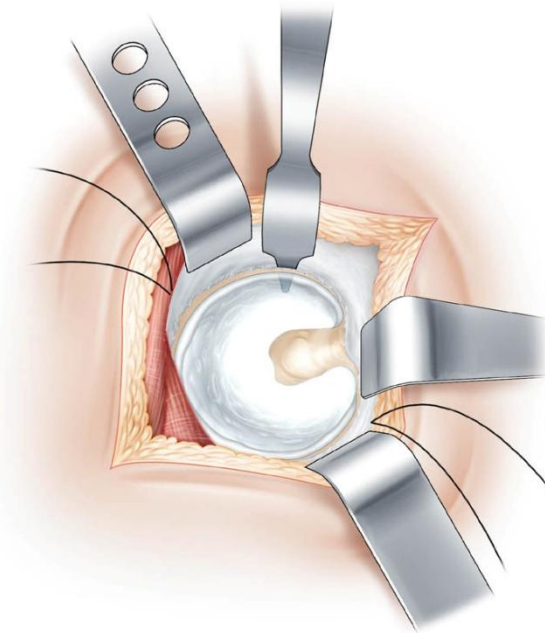
La capsule est ouverte en T



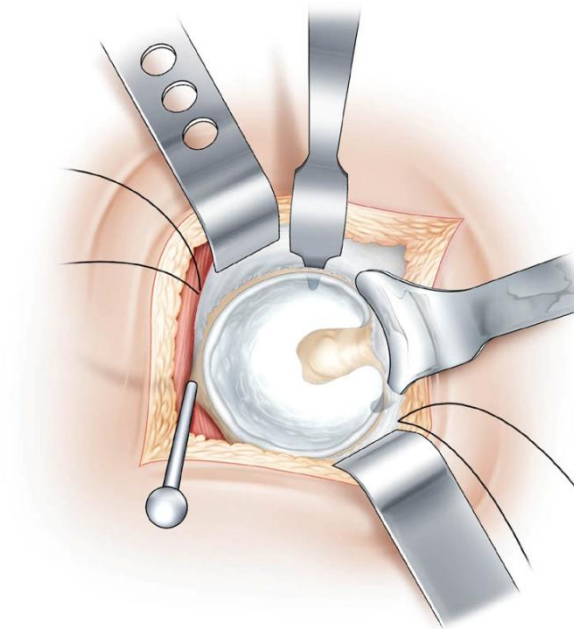
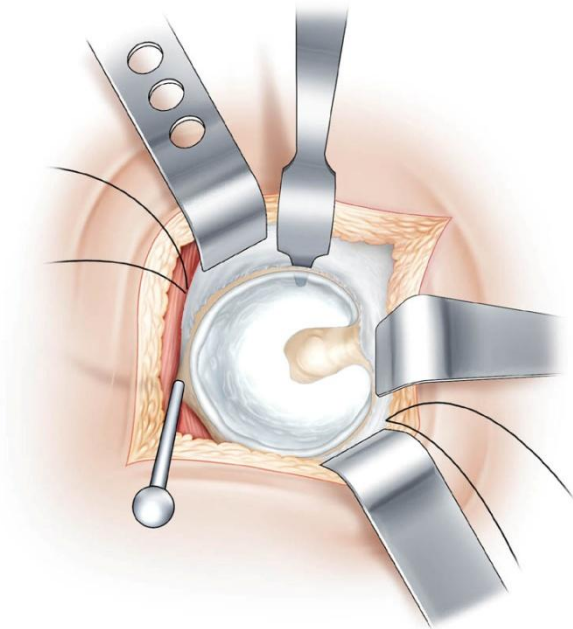
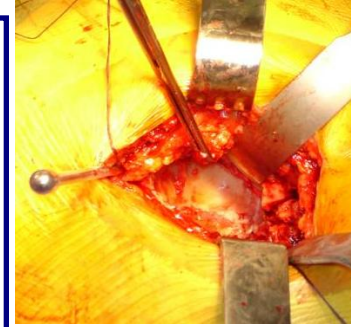
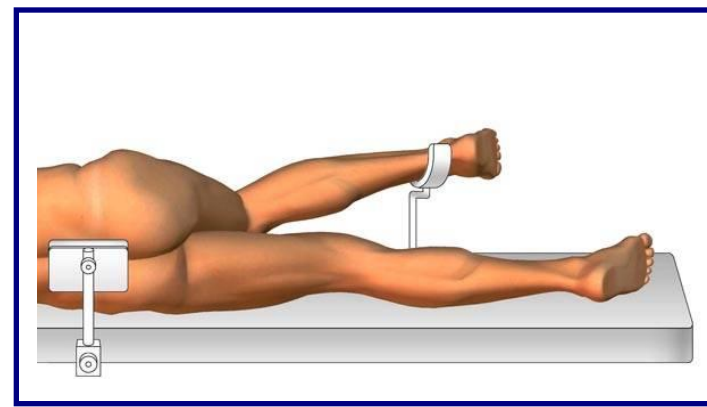
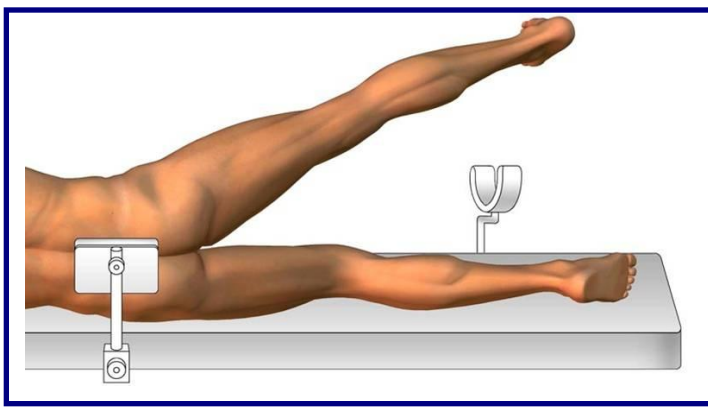
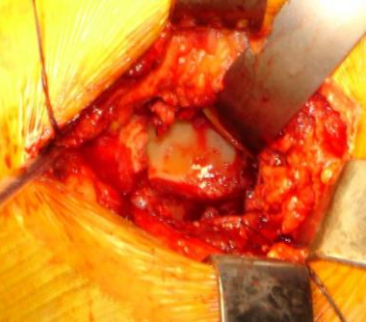Les 2 volets capsulaires sont placés sur fils tracteur



Luxation de hanche et section du col fémoral



**Exposition du cotyle :
L'écarteur s'accroche en avant de la corne antérieure du cotyle après perforation de la capsule**

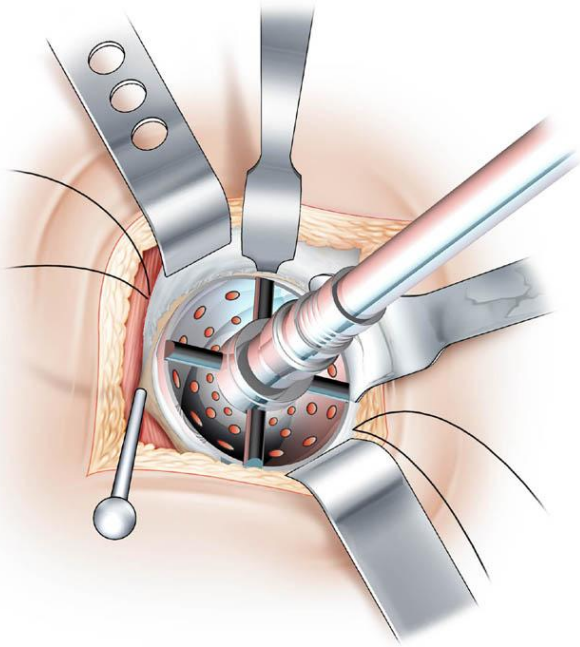
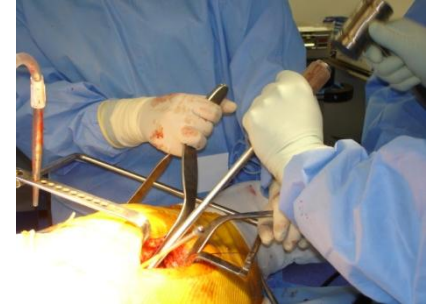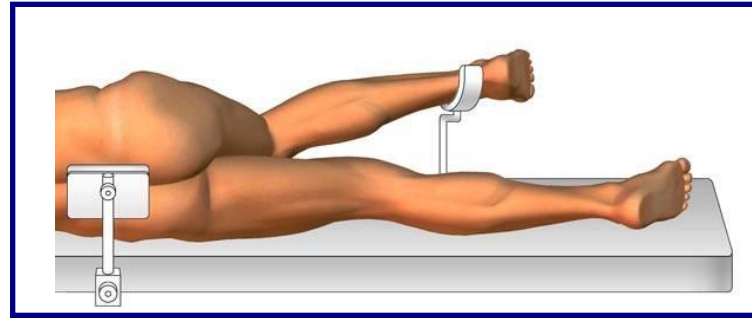
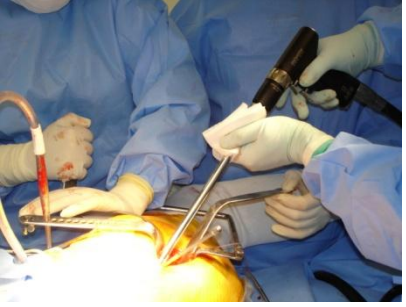


Exposition du cotyle :

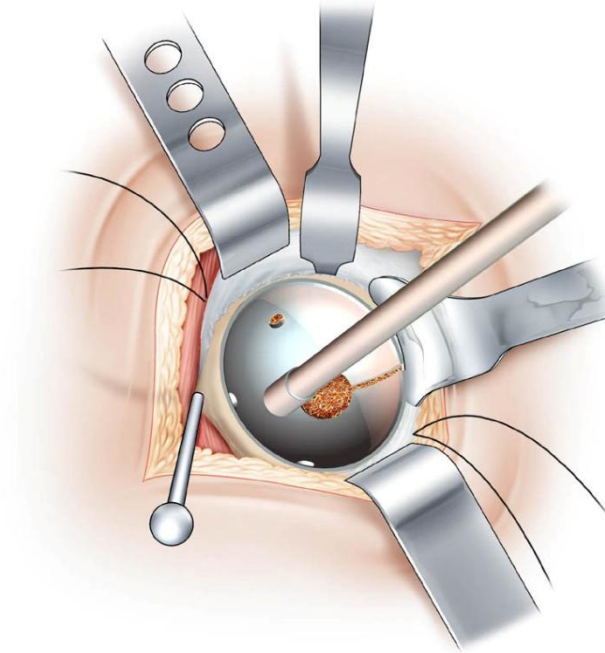
**Le piriformis est récliné vers le haut
Sa fixation est assurée par un clou de
Stenman incliné vers l'avant**

Exposition du cotyle :

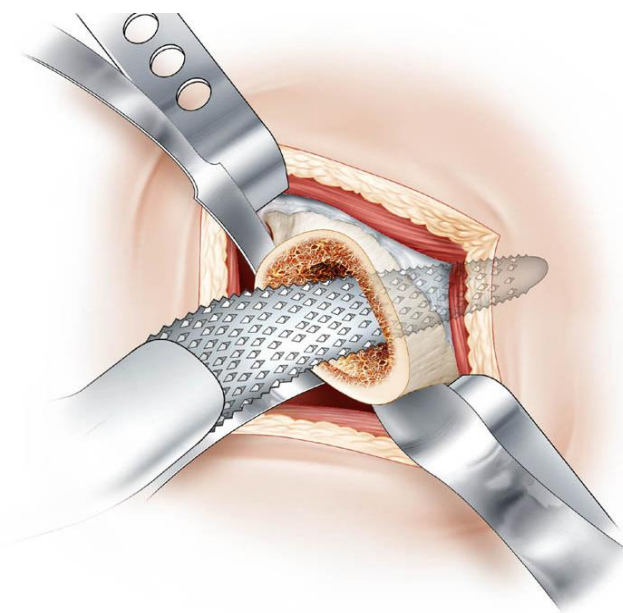
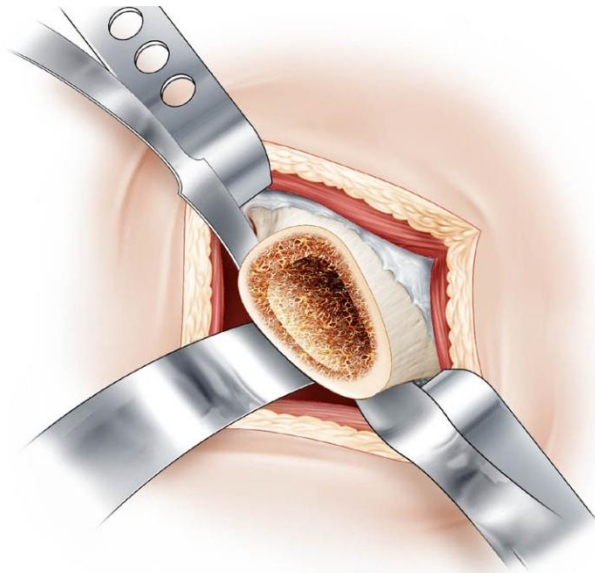
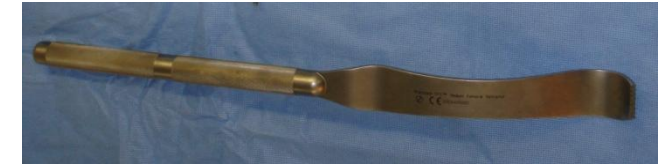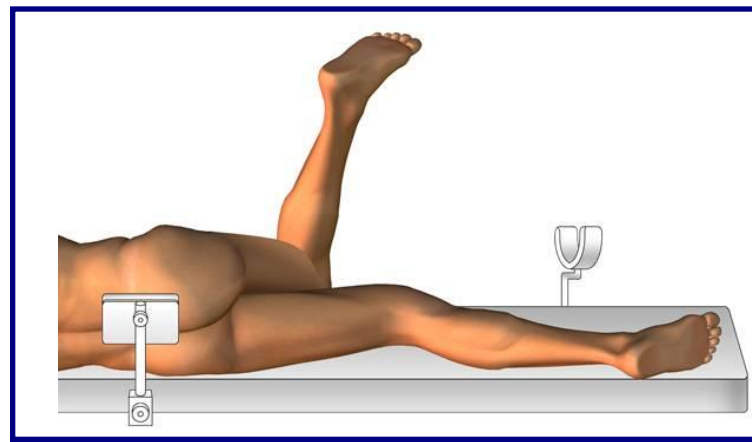
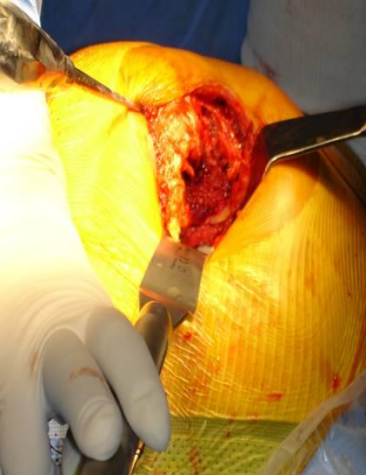
**L'écarteur inférieur est positionné
en dessous de la corne postérieure
après perforation de la capsule**



Fraisage du cotyle



Mise en place du cotyle

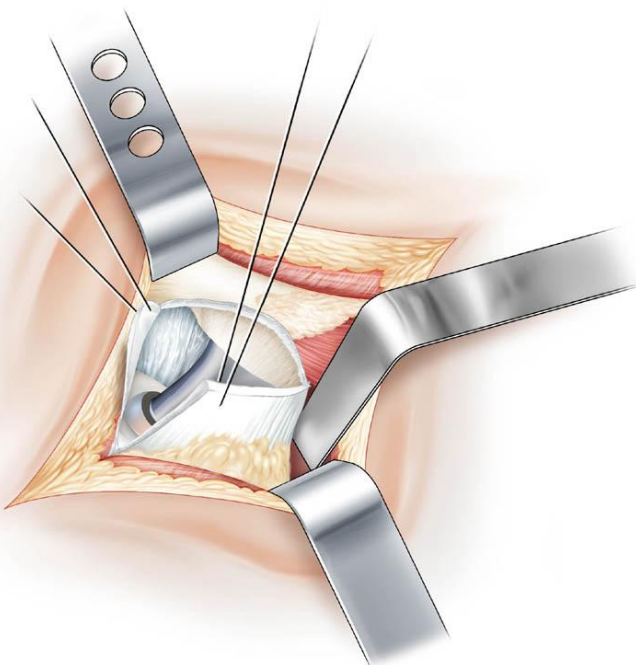
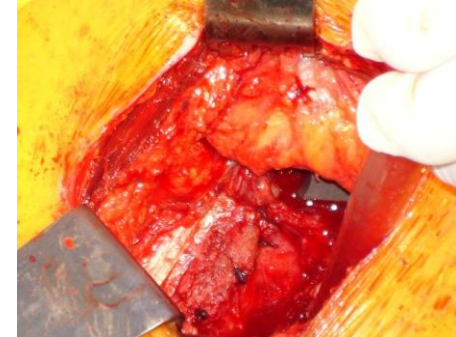
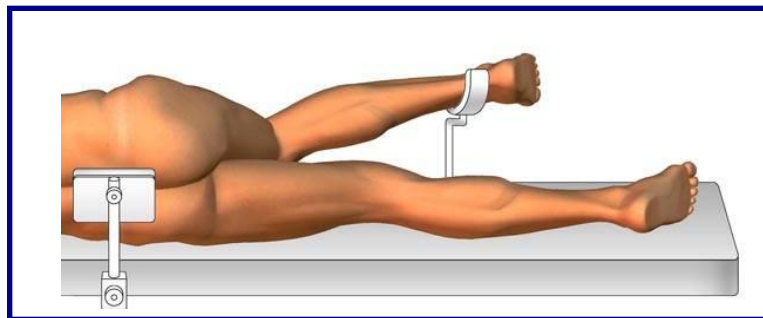
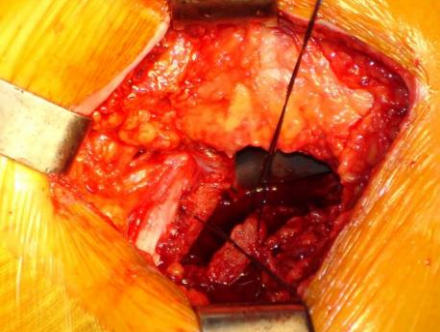


Préparation fémorale :

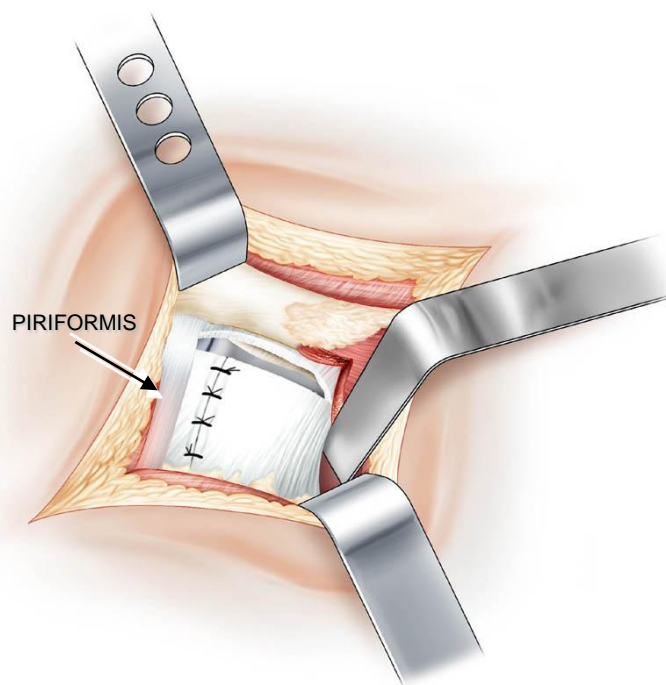
L'élevateur est placé sous le col fémoral

Passage des râpes droites successives

Remerciements à Mr .Donon, illustrateur médical,
pour ses dessins réalisés d'après documents photographiques



**Lors de la réduction prothétique
la traction sur les fils capsulaires
évite toute interposition**



**Fermeture de la capsule
Le piriformis reprend sa place**